



Non-Surgical Pneumoperitoneum: The Spectrum of Pneumatosis Cystoides

Neumoperitoneo no quirúrgico: el espectro de la neumatosis cistoide intestinal

Valentina Villegas González²
 María Andrea Calderón Ardila²
 Katherine Quintero Rodríguez¹
 Andrés Felipe Salinas Castro²
 Andrés Felipe Jaramillo Guevara³
 Juan Manuel Pérez Hidalgo¹



Key words (MeSH)

Pneumoperitoneum
 Pneumatosis cystoides
 intestinalis
 Multidetector computed
 tomography

Palabras clave (DeCS)

Neumoperitoneo
 Neumatosis cistoide
 intestinal
 Tomografía
 computarizada
 multidetector

Summary

Pneumatosis intestinalis is a condition that has traditionally been associated with poor general condition, poor prognosis and surgical management. However, there is a benign form of presentation that does not carry these implications and is called Pneumatosis Cystoides. This entity, characterized by the presence of gas-filled cysts inside the intestinal wall can generate pneumoperitoneum without evidence of signs of peritoneal irritation and resolve without surgical management need. The aim of this paper is to review the literature about pneumatosis intestinalis, focused on establishing its various etiologies and findings in different diagnostic modalities. Because diagnostic images have a key role in defining the management and need for surgical intervention of these patients, it is important that the radiologist knows and differentiate the different origins of pneumatosis intestinalis in images, as well as their possible implications. Proper communication with the treating service, can help determine the best form of management for the patient.

Resumen

La neumatosis intestinal es una condición que tradicionalmente se ha asociado a mal estado general, pobre pronóstico y manejo quirúrgico. No obstante, existe una forma de presentación benigna que no conlleva estas implicaciones y se denomina neumatosis cistoides. Esta entidad se caracteriza por la presencia de quistes llenos de gas en la pared intestinal, que pueden generar neumoperitoneo sin evidencia de signos de irritación peritoneal y que resuelven sin necesidad de manejo quirúrgico. El objetivo de este trabajo es realizar una revisión de la literatura acerca de la neumatosis intestinal, enfocado en el establecimiento de sus diversas etiologías y hallazgos en las diferentes modalidades diagnósticas. Debido a que las imágenes diagnósticas juegan un papel clave en el momento de definir el manejo y la necesidad de intervención quirúrgica de estos pacientes, es importante que el radiólogo conozca y pueda diferenciar los diferentes orígenes de la neumatosis intestinal en las imágenes, así como sus posibles implicaciones. Esto, asociado a una adecuada comunicación con el servicio tratante, puede ayudar a determinar la mejor forma de manejo para el paciente.

1. Introduction

Intestinal pneumatosis (intestinal coli pneumatosis, intestinal cystoid pneumatosis [ICP]) is a rare clinical entity, characterized by the presence of gaseous cysts without epithelial lining, with multinucleated giant cells (1) and content of hydrogen, nitrogen and carbon dioxide (2). These cysts are located inside the subserosal or submucosal layer of the intestine and in the portomesenteric vein complex. This description corresponds to a radiological finding, but not to a etiological diagnosis, since its origin can be associated with a wide range of entities, from benign processes to fulminant intestinal pathologies or even iatrogeny (3-6).

It was initially described in 1730 by Duo Vernoi (7), who based it on autopsy observations; in 1835 it was assigned the name of “pneumatosis” (8). However, it was until 1952 that the term “secondary pneumatosis” was added to describe the same entity with dependent origin in an established pathology and in events of iatrogenic character (3, 5, 9).

The incidence of this entity is 0.03% (10) and can occur in any age group (11), more frequently in older people (12). It is usually asymptomatic, and in cases with symptoms, they make consider secondary etiology. These etiologies are listed in Table 1 (13). Among the clinical manifestations are nonspecific symptoms, such as abdominal pain and distension, diarrhea with mucus, rectorrhagia, constipation, tenesmus, and weight loss;

¹Radiologist, Fundación Cardioinfantil IC. Bogotá, Colombia.

²Radiology Resident, Universidad del Rosario, Fundación Cardioinfantil IC. Bogotá, Colombia.

³Surgeon, University of Rosario. Bogotá, Colombia.

in a smaller percentage (3%) symptoms dependent on complications develop, such as volvulus, intestinal obstruction, tension pneumoperitoneum, bleeding, intussusception, and intestinal perforation (14, 15).

Table 1. Causes of Pneumatosis

Causes	
Benign	Lung: asthma, bronchitis, pneumonia, emphysema, cystic fibrosis.
	Systemic diseases: scleroderma, lupus, AIDS.
	Intestinal: pyloric stenosis, intestinal obstruction, peptic ulcer, inflammatory bowel disease, diverticulitis
	Iatrogeny: colon by enema, bypass, nasoenteral tube, endoscopy.
	Drugs: chemotherapy, lactulose, sorbitol.
	Organ transplantation: bone marrow, kidney, liver, heart, lung.
	Primary pneumatosis: idiopathic, cystoid intestinal pneumatosis.
Potentially fatal	Mesenteric ischemia, intestinal obstruction with strangulation, toxic megacolon, trauma

Etiopathogenesis

La etiopatogenia de la neumatosis intestinal es controvertida, por loThe etiopathogenesis of intestinal pneumatosis is controversial, and several theories have been proposed:

• **Mechanical theory.** Due to mucosal damage, gas penetrates the intestinal wall through lymphatic channels, then is distributed distally due to intestinal peristalsis. It may be the consequence of intestinal obstruction or surgical and endoscopic procedures that increase intraluminal pressure; however, this theory does not explain the high hydrogen content in the cysts (Figure 1) (5, 16, 17).

- **Bacterial theory.** Through a defect in the intestinal wall, hydrogen-producing bacteria (*Escherichia coli* and *Clostridium*) are displaced towards the submucosal layer and the lymphatic channels of the wall. This usually resolves with the administration of metronidazole (Figure 2) (18-21).
- **Lung theory.** The pulmonary pathologies mentioned in table 1 are accompanied by alveolar rupture producing pneumomediastinum and dissection by way of the aorta and mesenteric vessels until reaching the intestinal wall. Like mechanical theory, this does not clarify the high presence of hydrogen in cysts (Figure 3) (22-24).
- **Chemical or nutritional deficiency theory.** Malnutrition can interfere with the digestion of carbohydrates and increase bacterial fermentation in the intestine, generating high volumes of gas, which secondarily cause distension, ischemia and dissection of the gas through the submucosa (Figure 4) (22, 25).
- **Chemotherapy, biological therapy and connective tissue disease.** Some chemotherapy agents (fluorouracil) and biological therapy (rituximab, sunitinib, cetuximab, and gefitinib), as well as long-term administration of glucocorticoids, have been associated with the development of intestinal pneumatosis, since they generate atrophy and defects in the intestinal wall, leading to the formation of submucosal cysts (figures 5 and 6) (11, 26-28).

The involvement is usually in the large intestine (46%), followed by the small intestine (27%), with less involvement of the stomach, duodenum, mesentery, lymph nodes, omentum and peritoneum (11). In the primary form of the entity, segmental involvement with submucosal predilection in the left hemicolon or mesentery is frequent, while involvement of the subserosal layer occurs more frequently in the secondary form and occurs in the stomach, small intestine and right hemicolon, in a generalized or segmental manner (3).

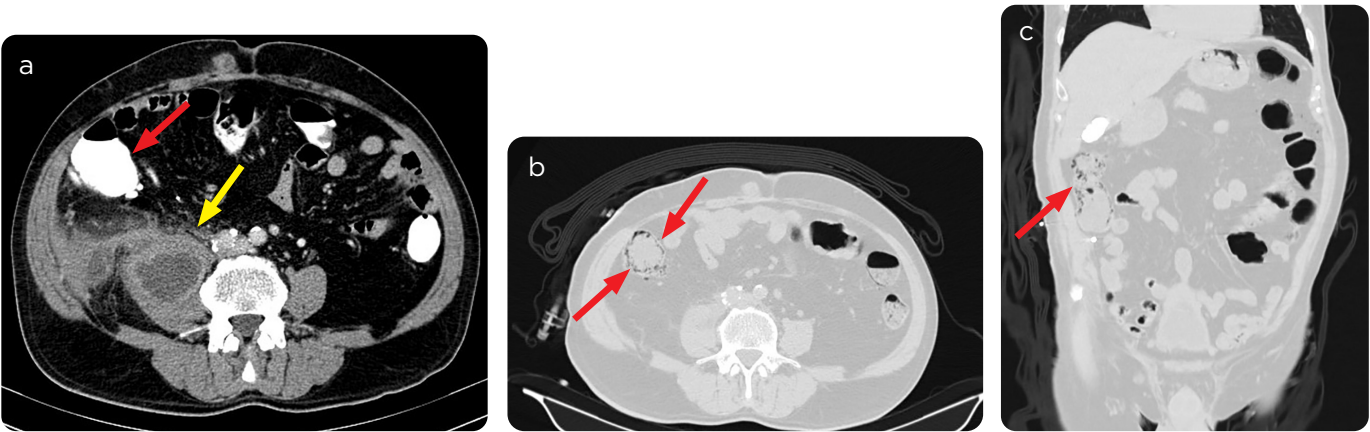


Figure 1. 71-year-old patient with sensation of mass in right iliac fossa. a): Abdominal CT scan on admission with collection in right iliac psoas muscle (yellow arrow), without evidence of pneumatosis in the neighboring colon (red arrow). b and c) Control CT scan after colonoscopy: it rules out masses in the colon and shows cystic images, of low density (arrows) in the mucosa of the ascending colon due to cystoid pneumatosis.

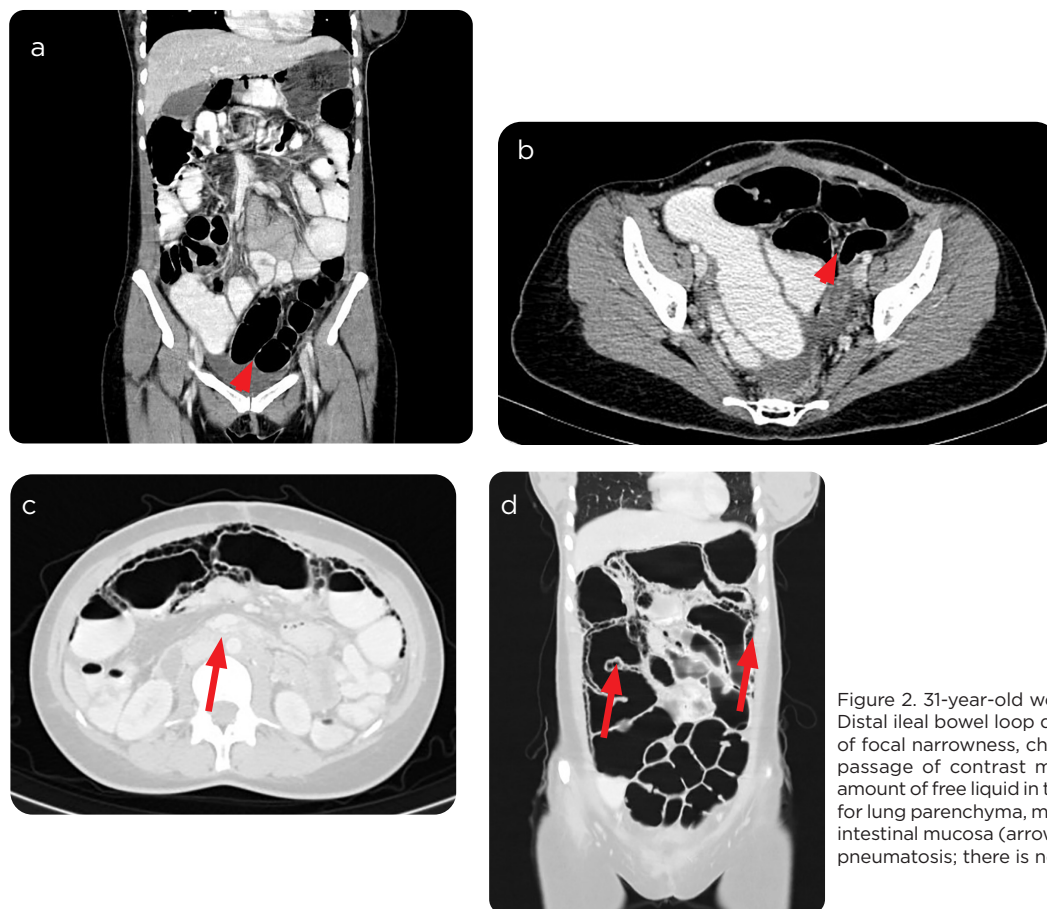


Figure 2. 31-year-old woman with abdominal pain. a and b) Distal ileal bowel loop distension (arrow), with several areas of focal narrowness, change in intestinal lumen caliber with passage of contrast medium to distal portion. Moderate amount of free liquid in the pouch bottom. c and d) In window for lung parenchyma, multiple linear and round images in the intestinal mucosa (arrows), which correspond to changes by pneumatosis; there is no pneumoperitoneum.

Figure 3. a and b) 29-year-old patient with history of asthma, cough and dyspnea. In the assessed segment of the abdomen, several low-density round images with air in close relation to the wall of the splenic angle of the colon (arrows) are identified, which due to their characteristics correspond to cystoid pneumatosis.

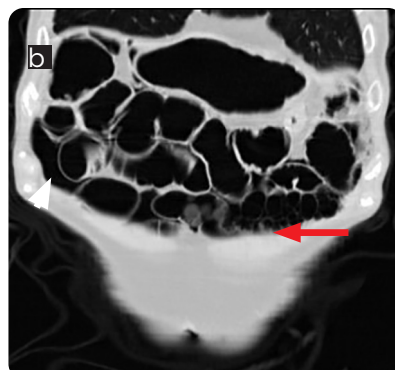
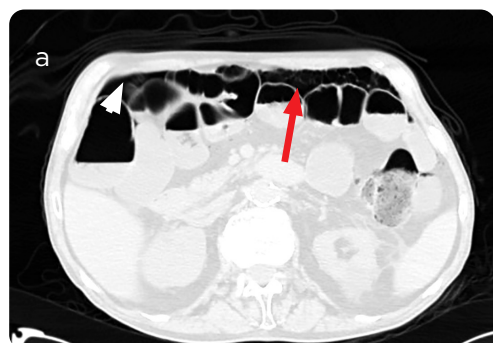
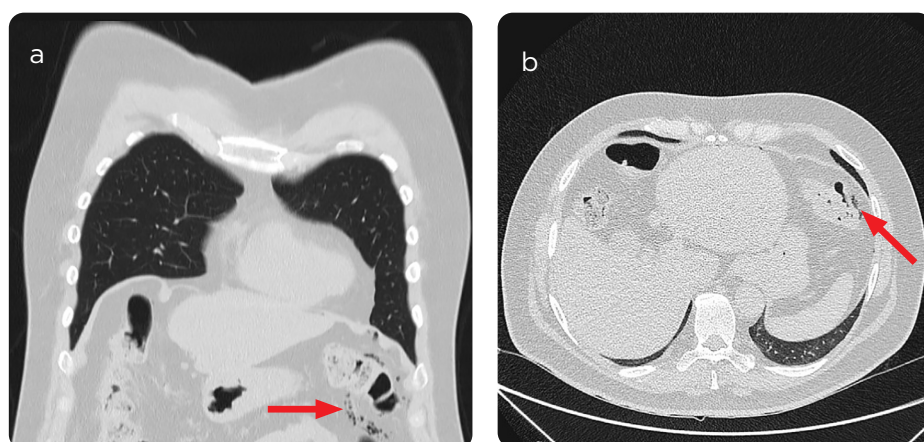


Figure 4. 90 year-old patient with a history of chronic malnutrition, admitted for urinary symptoms. a and b) In abdominal CT scan, assessed in window for lung parenchyma, rounded cystic images (arrows) are identified in close relation with intestinal mucosa and pneumoperitoneum chamber (arrow heads), findings secondary to cystoid pneumatosis.

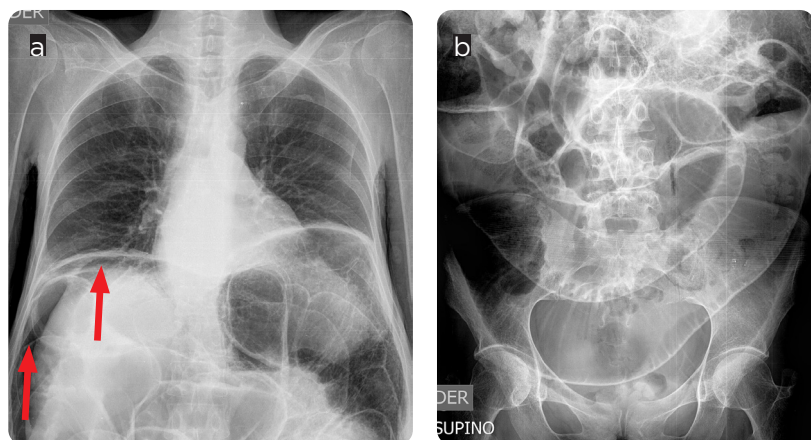


Figure 5. 39-year-old patient with history of scleroderma, admitted for abdominal pain. a and b) Abdominal radiography with distension of thin and colonic intestinal loops with pneumoperitoneum (arrows).

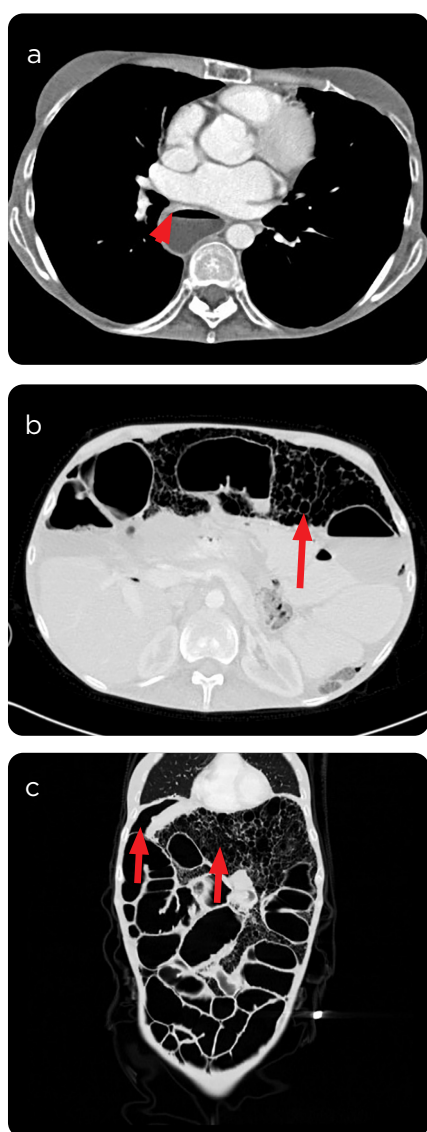


Figure 6. Abdominal scan of the same patient as the previous case. a) Significant esophageal dilation (arrowhead). b and c) Multiple cystic images in the intestinal mucosa and in the peritoneal cavity (arrows), associated with a pneumoperitoneum chamber (thick arrow), in relation to its base pathology.

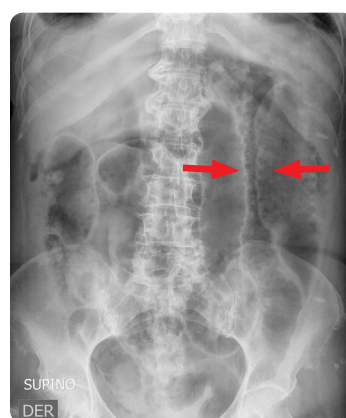

Figure 7. Abdominal Rx: multiple radiolucent images are identified along the colon wall, configuring the sign of the double wall (arrows).

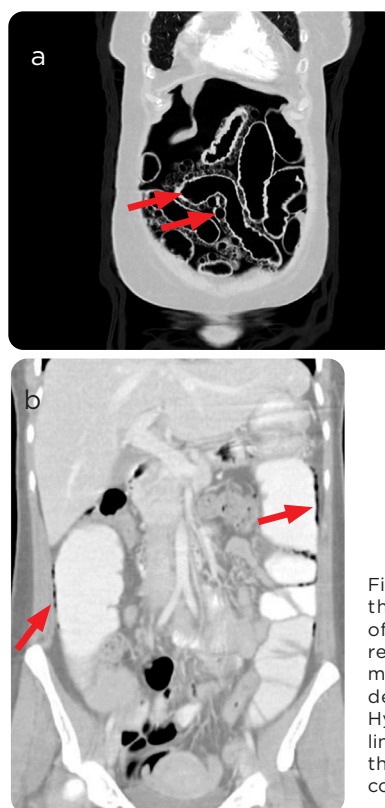


Figure 8. a) Abdominal CT scan that allows a clear definition of the cystic images and their relationship with the intestinal mucosa (arrows), as well as moderate pneumoperitoneum. b) Hypodense muscular images of linear configuration in the wall of the ascending and descending colon (arrows).

The diagnosis is imaging, and it is a determining factor in the management, due to the significant percentage of unnecessary surgical interventions (27%) in the context of intestinal pneumatosis of benign cause (29-31).

Imaging findings

Simple abdominal radiography is the first image used in the diagnostic approach (32), due to the non-specific symptoms of the patients. In this one, the sign of the “double wall” (Rigler sign), pneumoperitoneum or rounded radiolucent collections in the intestinal wall, similar to a bunch of grapes, becomes evident (Figure 7). In the colon, by enema, rounded filling defects are visualized in the intestinal wall, which produce a scalloped outline towards the intestinal lumen. These defects can simulate polyps when visualized from a frontal projection; however, in the lateral projection, the cysts can be clearly identified within the colonic wall (3, 33).

Computed tomography (CT) is the diagnostic modality of choice, with greater sensitivity than abdominal radiography. It allows clarifying ambiguous findings (34, 35). Likewise, it orients the possible cause of the process, evaluates complications and directs up to 50% of the patients to non-surgical management (12, 29, 36, 37). The main finding in the CT is the thickening of the intestinal wall, which is associated with low-density mucosal or submucosal images; they are described in three types of cystic, circular or circumferential, and linear patterns, which may overlap in some cases. The first suggests a benign process, while the last two may be due to benign or secondary causes (Figure 8).

Misdiagnosis of intestinal pneumatosis occurs due to the failure to differentiate between the air of the intestinal contents and the air that is located between the folds of the mucosa of the colon, so it is always recommended to use the lung window in CT for better characterization (38,39). It is essential to recognize the decrease in the enhancement of the intestinal wall, arterial or venous occlusion, striation of mesenteric fat, mesenteric vascular ingurgitation, ascites, intestinal pneumatosis and portal pneumatosis (low-density tubular images, branched towards the periphery of the liver), since these findings suggest intestinal ischemia and carry a high risk of mortality.

The use of ultrasound to avoid exposure to ionizing radiation has been described in the approach to the pediatric population. In this examination, linear, focal, or continuous echogenic ring areas may be found within the intestinal wall. With respect to CT in children, the alarming findings are similar to those of adults (11, 29, 40-43).

Magnetic resonance imaging (MRI) makes it possible to visualize circumferential collections of air attached to the intestinal wall, which are more evident in eco-gradient acquisitions due to the heterogeneity of the magnetic field at the tissue-air interface, which generates the artifact of “blooming” (42).

In colonoscopy two different patterns can be observed: the “bubble” pattern, usually idiopathic, which must be differentiated from polyposis; the “grape cluster” pattern is similar to the intestinal tuberculosis and must be distinguished from tumors and Crohn’s disease (11).

Treatment

Laparotomy is indicated in patients with signs of medically untreatable acute abdomen, in which a gastrointestinal cause is identified: intestinal ischemia, obstruction, hemorrhage or peritonitis, which must

be managed urgently (44). Currently, the mortality of these patients varies between 25-35%; thanks to the detection by means of diagnostic images, it is decreasing with respect to what was reported by Liebman and collaborators in 1878, where mortality of 75% was observed (45). In studies conducted by Treyaud et al. and Nindu et al., leukocytosis, elevated BUN, and hyperlactation (> 2.0 mmol/L) were identified as predictors of surgical intervention, associated with peritoneal irritation, tachycardia, and small bowel dilation (33,46,47). Patients with good general condition, without signs of peritoneal irritation, with absence of metabolic acidosis, ascites and renal failure, are considered for conservative treatment with oxygen therapy. By increasing the partial pressure of oxygen in the blood, the gas pressure gradient in the cysts is increased, which release this gas and fill up with oxygen, which will be metabolized later. Other conservative treatment options include nasogastric decompression, intestinal rest, and antibiotic therapy (3,4,48-50).

Conclusion

Cystoid pneumatosis is an infrequent entity with a poorly understood etiology, associated with multiple intestinal and extraintestinal conditions. Imaging plays an important role in its diagnostic approach. It is necessary for radiologists and other medical specialties to be familiar with this entity in order to manage it correctly and avoid unnecessary surgical procedures

References

- Muñoz G, Moros M, Ortego FJ. Neumatosis quística intestinal: presentación de tres casos y revisión de la literatura. *Rev Españ Patol*. 2012;45(2):100-4.
- Read NW, Al-Janabi MN, Cann PA. Is raised breath hydrogen related to the pathogenesis of pneumatosis coli? *Gut*. 1984;25(8):839-45.
- Arikanoglu Z. Pneumatosis cystoides intestinalis: A single center experience. *WJG*. 2012;18(5):453.
- Azzaroli F. Pneumatosis cystoides intestinalis. *WJG*. 2011;17(44):4932.
- Gómez N, Ayón J, Stanley Y, Cavedes A. Neumatosis intestinal. *Acta Gastroenterol Latinoam*. 2015;45(3):225-9.
- Pear B. Pneumatosis intestinalis a review. *Radiology*. 1998;207(1):13-9.
- Morris MS, Gee AC, Cho SD, Limbaugh K, Underwood S, Ham B, et al. Management and outcome of pneumatosis intestinalis. *Am J Surg*. 2008;195(5):679-83.
- Koss LG. Abdominal gas cysts (pneumatosis cystoides intestinorum hominis), an analysis with a report of a case and a critical review of the literature. *AMA Archives Pathol*. 1952;53:523-49.
- Greenstein AJ, Nguyen SQ, Berlin A, Corona J, Lee J, Wong E, et al. Pneumatosis intestinalis in adults: Management, surgical indications, and risk factors for mortality. *J Gastrointest Surg*. 2007;11(10):1268-74.
- Heng Y, Schuffler MD, Haggitt RC, Rohrmann CA. Pneumatosis intestinalis: a review. *AM J Gastroenterol*. 1995;90:1747-58.
- Wang Y, Wang Y, Zheng Y, Jiang H, Zhang J. Pneumatosis cystoides intestinalis: six case reports and a review of the literature. *BMC Gastroenterol*. 2018;18(1):100.
- Khalil P, Huber-Wagner S, Ladurner R, Kleespies A, Siebeck M, Mutschler W, et al. Natural history, clinical pattern, and surgical considerations of pneumatosis intestinalis. *Eur J Med Res*. 2009;14(6):231.
- Gelman SF, Brandt, Lawrence J. Pneumatosis intestinalis and AIDS: A case report and review of the literature. *Am J Gastroenterol*. 1998;93(4):5.
- Frossard J-L, Braude P, Berney J-Y. Computed tomography colonography imaging of pneumatosis intestinalis after hyperbaric oxygen therapy: a case report. *J Med Case Reports*. 2011;5(1):375.
- Adamiak T, Rudolph C. Pneumatosis Coli. *J Pediatr Gastroenterol Nutr*. 2008;46(2):123.
- Sebastià C, Quiroga S, Espin E, Boyé R, Álvarez-Castells A, Armengol M. Portomesenteric vein gas: Pathologic mechanisms, CT findings, and prognosis. *RadioGraphics*. 2000;20(5):1213-24.
- St. Peter SD, Abbas MA, Kelly K. The spectrum of pneumatosis intestinalis. *Arch Surg*. 2003;138(1):68.
- Kang G. Benign pneumatosis intestinalis. *Can Fam Physician*. 2017;63(10):766-8.
- Donati F, Boraschi P, Giusti S, Spallanzani S. Pneumatosis cystoides intestinalis: Imaging findings with colonoscopy correlation. *Dig Liver Dis*. 2007;39(1):87-90.

20. Tak PP, Van Duinen CM, Bun P, Eulderink F, Kreuning J, Gooszen HG, et al. Pneumatosis cystoides intestinalis in intestinal pseudoobstruction: Resolution after therapy with metronidazole. *Digest Dis Sci.* 1992;37(6):949-54.
21. Gagliardi G, Thompson IW, Hershman MJ, Forbes A, Hawley PR, Talbot IC. Pneumatosis coli: a proposed pathogenesis based on study of 25 cases and review of the literature. *Int J Colorectal Dis.* 1996;11(3):111-8.
22. Wu L-L. A systematic analysis of pneumatosis cystoides intestinalis. *WJG.* 2013;19(30):4973.
23. Schröpfer E, Meyer T. Surgical aspects of pneumatosis cystoides intestinalis: two case reports. *Cases J.* 2009;2(1):6452.
24. Keyting WS, McCarver RR, Kovarik JL, Daywitt AL. Pneumatosis intestinalis: A new concept. *Radiology.* 1961;76(5):733-41.
25. Feezko PJ, Mezwa DG, Farah MC, White BD. Clinical significance of pneumatosis of the bowel wall. *RadioGraphics.* 1992;12:1069-78.
26. Petrides C, Kyriakos N, Andreas I, Konstantinos P, Chrysanthos G, Athanasios P, et al. Pneumatosis cystoides intestinalis after cetuximab chemotherapy for squamous cell carcinoma of parotid gland. *Case Reports in Surgery.* 2015;2015:1-3.
27. Sagara A, Kitagawa K, Furuichi K, Kitajima S, Toyama T, Okumura T, et al. Three cases of pneumatosis intestinalis presenting in autoimmune diseases. *Modern Rheumatology.* 2012;22(4):610-5.
28. Groninger E, Hulscher JBF, Timmer B, Tamminga RYJ, Broens PMA. Free air intraperitoneally during chemotherapy for acute lymphoblastic leukemia: Consider pneumatosis cystoides intestinalis. *J Pediatr Hematol/Oncol.* 2010;32(2):141-3.
29. Goyal R, Lee HK, Akerman M, Mui LW. Clinical and imaging features indicative of clinically worrisome pneumatosis: key components to identifying proper medical intervention. *Emerg Radiol.* 2017;24(4):341-6.
30. Lerner HH, Gazin AL. Pneumatosis intestinalis: Its roentgenologic diagnosis. *AM J Roentgenol.* 1946;56:464-9.
31. Saul T, Palamidessi N. Pneumatosis intestinalis. *J Emerg Med.* 2011;40(5):545-6.
32. Sequeira W. Pneumatosis cystoides intestinalis in systemic sclerosis and other diseases. *Sem Arthr Rheumat.* 1990;19(5):269-77.
33. Treyaud M-O, Duran R, Zins M, Knebel J-F, Meuli RA, Schmidt S. Clinical significance of pneumatosis intestinalis – correlation of MDCT-findings with treatment and outcome. *Eur Radiol.* 2017;27(1):70-9.
34. Rahim H. Gastrointestinal sarcoidosis associated with pneumatosis cystoides intestinalis. *WJG.* 2013;19(7):1135.
35. Devgun P, Hassan H. Pneumatosis Cystoides Intestinalis: A Rare Benign Cause of Pneumoperitoneum. *Case Reports Radiol.* 2013;2013:1-3.
36. Braumann C, Menenakos C, Jacobi CA. Pneumatosis intestinalis — a pitfall for surgeons? *Scand J Surg.* 2005;94(1):47-50.
37. Zhang H, Jun SL, Brennan TV. Pneumatosis intestinalis: Not always a surgical indication. *Case Reports Surg.* 2012;2012:1-3.
38. Soyer P, Martin-Grivaud S, Boudiaf M, Malzy P, Duchat F, Hamzi L, et al. Linear or bubbly: a pictorial review of CT features of intestinal pneumatosis in adults. *J Radiol.* 2008;89(12):1907-20.
39. Lassandro F, Valente T, Rea G, Lassandro G, Golia E, Brunese L, et al. Imaging assessment and clinical significance of pneumatosis in adult patients. *Radiol Med.* 2015;120(1):96-104.
40. Ko S, Hong SS, Hwang J, Kim H, Chang Y-W, Lee E. Benign versus life-threatening causes of pneumatosis intestinalis: differentiating CT features. *Rev Assoc Med Bras.* 2018;64(6):543-8.
41. Olson DE, Kim Y-W, Ying J, Donnelly LF. CT Predictors for differentiating benign and clinically worrisome pneumatosis intestinalis in children beyond the neonatal period. *Radiology.* 2009;253(2):513-9.
42. Ho LM, Paulson EK, Thompson WM. Pneumatosis intestinalis in the adult: benign to life-threatening causes. *Am J Roentgenol.* 2007;188(6):1604-13.
43. Kim KM, Lee CH, Kim KA, Park CM. CT Colonography of pneumatosis cystoides intestinalis. *Abdom Imaging.* 2007;32(5):602-5.
44. Kala Z, Hermanova M, Kysela P. Laparoscopically assisted subtotal colectomy for idiopathic pneumatosis cystoides intestinalis. *Acta Chirurgica Belgica.* 2006;106(3):346-7.
45. Naguib N, Mekhail P, Gupta V, Naguib N, Masoud A. Portal venous gas and pneumatosis intestinalis; radiologic signs with wide range of significance in surgery. *J Surg Educat.* 2012;69(1):47-51.
46. Bani Hani M, Kamangar F, Goldberg S, Greenspon J, Shah P, Volpe C, et al. Pneumatosis and portal venous gas: do CT findings reassure? *J Surg Res.* 2013;185(2):581-6.
47. Umapathi BA, Friel CM, Stukenborg GJ, Hedrick TL. Estimating the risk of bowel ischemia requiring surgery in patients with tomographic evidence of pneumatosis intestinalis. *Am J Surg.* 2016;212(4):762-8.
48. Furihata T, Furihata M, Ishikawa K, Kosaka M, Satoh N, Kubota K. Does massive intraabdominal free gas require surgical intervention? *WJG.* 2016;22(32):7383.
49. Aziret M, Erdem H, Ülgen Y, Kahraman Ş, Çetinköner S, Bozkurt H, et al. The appearance of free-air in the abdomen with related pneumatosis cystoides intestinalis: Three case reports and review of the literature. *Int J Surg Case Reports.* 2014;5(12):909-13.
50. Mizoguchi F, Nanki T, Miyasaka N. Pneumatosis cystoides intestinalis following lupus enteritis and peritonitis. *Intern Med.* 2008;47(13):1267-71.

Correspondence

Valentina Villegas González
Carrera 20B # 65A-46
Manizales, Colombia
valenvillegas1989@hotmail.com

Received for evaluation: January 27, 2020

Accepted for publication: February 15, 2020